UpToDate®
Official reprint from UpToDate®
www.uptodate.com © 2026 UpToDate, Inc. and/or its affiliates. All Rights Reserved.

Evaluation and management of the adrenal incidentaloma

AUTHORS: William F Young, Jr, MD, MSc, Electron Kebebew, MD, FACS
SECTION EDITORS: Lynnette K Nieman, MD, Sally E Carty, MD, FACS
DEPUTY EDITORS: Katya Rubinow, MD, Wenliang Chen, MD, PhD

All topics are updated as new evidence becomes available and our peer review process is complete.

Literature review current through: **Feb 2026.**
This topic last updated: **Sep 25, 2024.**

INTRODUCTION

An adrenal incidentaloma is a mass lesion greater than 1 cm in diameter, serendipitously discovered by radiologic examination [1]. This entity is the result of technological advances in imaging such as computed tomography (CT) and magnetic resonance imaging (MRI) and their widespread use in clinical practice. Discovery of an adrenal mass raises two questions that determine the degree of evaluation and the need for therapy, and both questions should be addressed simultaneously [2]:

- Is it malignant?
- Is it functioning?

The approach to the evaluation and management of adrenal incidentalomas is reviewed here. Detailed discussions of adrenal carcinoma and functioning adrenal tumors such as pheochromocytomas and aldosteronomas are found elsewhere. (See "Clinical manifestations and diagnosis of adrenocortical carcinoma" and "Clinical presentation and diagnosis of pheochromocytoma" and "Pathophysiology and clinical features of primary aldosteronism".)

PREVALENCE

Unilateral masses — Adrenal masses may be found incidentally when CT scans or MRI is done for other reasons. In a study of 61,054 abdominal CT scans performed from 1985 to 1990, an incidental adrenal tumor (incidentaloma >1 cm) was detected in 259 patients (0.4 percent of all

CT scans) [3]. Subsequent studies, utilizing higher-resolution scanners, have reported a prevalence of adrenal incidentaloma on abdominal CT from 1.4 to 7.3 percent [4-6]. The prevalence of adrenal incidentaloma is higher in older patients (10 percent) [7].

In a cross-sectional study in which 25,356 volunteers had abdominal CT scans as part of a general health evaluation, adrenal tumors were detected in 351 patients (1.4 percent) [5]. The prevalence of adrenal masses increased with age (0.28 versus 3.2 percent in patients aged <35 and >65 years, respectively) [5].

In autopsy studies, the prevalence of incidentalomas is 2 percent, and it ranges from 1 to 9 percent. The prevalence is higher in individuals with obesity, diabetes, and hypertension [7]. As an example, in a series of 739 autopsies, adrenal masses between 2 mm and 4 cm in size were present in 9 percent of individuals without hypertension and in 12 percent of those with hypertension [8].

Bilateral masses — Analyses from two large adrenal incidentaloma studies with 887 and 202 patients showed that bilateral masses were found in 10 to 15 percent of cases [9,10]. Bilateral adrenal masses can be seen with metastatic disease, congenital adrenal hyperplasia, cortical adenomas, lymphoma, infection (eg, tuberculosis, fungal), hemorrhage, corticotropin (ACTH)-dependent Cushing syndrome, pheochromocytoma, primary aldosteronism, amyloidosis, infiltrative disease of the adrenal glands, and primary bilateral macronodular adrenal hyperplasia (PBMAH). In one study of 208 adrenal incidentaloma patients, 19 (9 percent) proved to have adrenal metastases; 10 of the 19 patients (53 percent) had bilateral disease [11].

In some patients with bilateral disease, one adrenal mass proves to be a nonfunctioning cortical adenoma, while the contralateral adrenal mass is hormone secreting [10]. In addition, adrenocortical hypofunction may occur in patients with bilateral adrenal masses. Therefore, all patients with bilateral adrenal masses should be screened for adrenocortical hyper- and hypofunction.

EVALUATION FOR MALIGNANCY

Malignancy is an uncommon cause of adrenal incidentaloma in patients without a known diagnosis of cancer. Although estimates have varied widely, the actual frequency of primary adrenal carcinoma in patients with adrenal incidentaloma is approximately 2 to 5 percent; another 0.7 to 2.5 percent have non-adrenal metastases to the adrenal gland [1,7,12-14]. The size and imaging characteristics ("imaging phenotype") of the mass may help risk stratify for possible malignancy [1,13,15].

Size — The maximum diameter of the adrenal mass is predictive of malignancy [16]. This was illustrated in a study of 887 patients with adrenal incidentalomas from the National Italian Study Group on Adrenal Tumors [9]. Adrenocortical carcinomas were significantly associated with mass size, with 90 percent being more than 4 cm in diameter when discovered.

Adrenal mass size is also important because the smaller the adrenocortical carcinoma is at the time of diagnosis, the better the overall prognosis. In a retrospective review of 62 patients with adrenocortical carcinoma, five-year survival was approximately 16 percent overall, but much higher (42 percent) in patients with smaller tumors (stages I and II, confined to the adrenal gland) who were more likely to undergo curative resection [17]. (See "Clinical manifestations and diagnosis of adrenocortical carcinoma" and "Treatment of adrenocortical carcinoma".)

In the report from the National Italian Study Group, a 4 cm cutoff had a 93 percent sensitivity of detecting adrenocortical carcinoma, even though specificity was limited (76 percent of masses larger than 4 cm in diameter were benign) [9,13]. In the Mayo Clinic study cited above, all 20 adrenal carcinomas were between 4 and 6 cm in diameter [3]. Therefore, surgical removal of unilateral adrenal masses larger than 4 cm should be considered to avoid missing adrenal carcinomas, particularly in younger patients. (See 'Management' below.)

However, adrenal mass size should not be used as the only parameter to guide treatment. In a retrospective, single-center cohort of 4085 patients with adrenal tumors, 705 (17 percent) had adrenal masses measuring 4 cm or more in diameter; of these, 216 (31 percent) were adrenocortical adenomas, 158 (22 percent) were pheochromocytomas, 116 (16 percent) were other benign adrenal tumors, 88 (13 percent) were adrenocortical carcinomas, and 127 (18 percent) were other malignant tumors [18]. On multivariate analysis, older age at diagnosis, male sex, nonincidental mode of discovery, larger tumor size, and higher unenhanced CT attenuation were all found to be statistically significant predictors of malignancy [18]. (See 'Imaging phenotype' below and 'Monitoring when surgery not performed' below.)

Imaging phenotype — CT or MRI with 2 to 3 mm cuts may allow prediction of the histologic type of the adrenal tumor [1,9]. As an example, the lipid-rich nature of a cortical adenoma is helpful in distinguishing this benign tumor from carcinoma (image 1).

CT scan — Noncontrast CT is the preferred initial imaging test for evaluating adrenal incidentalomas [19,20].

Unenhanced attenuation — On CT scanning, the density of the image (black is less dense) is attributed to radiograph attenuation. The intracytoplasmic fat in adenomas results in low attenuation on unenhanced CT; non-adenomas have higher attenuation in unenhanced CT. The Hounsfield scale is a semiquantitative method of measuring radiograph attenuation.

Typical precontrast Hounsfield unit (HU) values are -20 to -150 HU for adipose tissue and 20 to 150 HU for kidney. If an adrenal mass measures <10 HU on unenhanced CT (ie, has the density of fat), the likelihood that it is a cortical adenoma is nearly 100 percent. However, up to 30 percent of adenomas do not contain large amounts of lipid and may be indistinguishable from non-adenomas on nonenhanced CT scans and are termed **lipid-poor** adenomas. Although imaging phenotype does not predict hormonal function, it does predict underlying pathology, and surgical resection should be considered in patients with adrenal incidentalomas that have a suspicious imaging phenotype [1]. (See 'Typical imaging features' below.)

- **HU<10** – A consensus panel noted that a homogeneous adrenal mass with a smooth border and an attenuation value <10 HU on unenhanced CT is very likely to be a cortical adenoma [2]. This appears to be a reasonable CT HU cutoff based upon a retrospective analysis of 151 patients with adrenal masses who underwent both a noncontrast CT scan and adrenalectomy [21]. The mean HU (± standard deviation [SD]) for adrenal adenomas/hyperplasia was significantly lower than for adrenal carcinomas, metastases, and pheochromocytomas (16.2±13.6 versus 36.9±4.1, 39.2±15.2, and 38.6±8.2, respectively). The only patients in the nonadenoma groups with a noncontrast CT HU <10 were those with myelolipomas (which were all less than -40 and therefore easily distinguishable). In this series, an unenhanced CT attenuation ≤10 HU or a combination of tumor size ≤4 cm and HU ≤20 excluded non-adenomas in 100 percent of cases.

- **HU>10** – In a retrospective cohort study of 353 patients with adrenal nodules who underwent adrenal biopsy and/or adrenalectomy, 80 percent of patients presented with known or suspected extra-adrenal malignancy [22]. Adrenal masses with unenhanced CT attenuation >10 HU diagnosed malignancy with a sensitivity of 100 percent, specificity of 33 percent, positive predictive value (PPV) of 72 percent, and negative predictive value (NPV) of 100 percent. Unenhanced CT attenuation of ≤10 HU excluded malignancy even in this high-risk population.

Delayed contrast-enhanced CT — Initial studies suggested that on delayed contrast-enhanced CT, the rapidity of contrast medium washout could distinguish between adrenal adenoma and non-adenomas [23]. Ten minutes after administration of contrast, an absolute contrast medium washout of more than 50 percent was reported to be 100 percent sensitive and specific for adenoma when patients with adenomas were compared with those with carcinomas, pheochromocytomas, and metastases [24,25]. However, contrast medium washout may have limited utility for excluding malignancy and pheochromocytoma in indeterminate, lipid-poor nodules. One retrospective study of adrenal nodules with an attenuation value of >10 HU found that contrast washout greater than 60 percent had

substantially lower sensitivity (77.5 percent) and specificity (70 percent) for adenoma in adrenal masses <4 cm [26].

MRI — Although CT is the recommended primary adrenal imaging procedure in most cases, MRI has advantages in certain clinical situations. For example, follow-up imaging with MRI avoids the radiation exposure of repeated CT imaging.

- Conventional spin-echo MRI is the most frequently used technique. Using low or mid-field-strength magnets, T1- and T2-weighted imaging can distinguish adenomas from malignancy and pheochromocytoma.

- MR with chemical shift imaging (CSI) accurately distinguishes adrenal adenomas from non-adenomas based on their elevated amounts of intracytoplasmic fat [27]. In a meta-analysis of 1280 lesions (859 adenomas), CSI demonstrated a sensitivity of 94 percent (95% CI 88-97 percent) and a specificity of 95 percent (95% CI 89-97 percent). No difference in diagnostic performance was seen when quantitative versus qualitative image analysis was compared.

Other — Positron emission tomography (PET) with either fludeoxyglucose F 18 (FDG) [28-30] or 11C-metomidate (MTO) [31] can be helpful in selected patients (eg, those with a prior history of malignancy or those in which unenhanced CT attenuation or washout analysis is inconclusive or suspicious for malignancy [7]) because of their high sensitivity for detecting malignancy [1]. (See "Clinical manifestations and diagnosis of adrenocortical carcinoma", section on 'Radiographic studies'.)

Typical imaging features — The imaging characteristics of adrenal masses are summarized here.

Cortical adenomas

- Round and homogeneous density, smooth contour, and sharp margination [32]

- Diameter less than 4 cm, unilateral location

- Low unenhanced CT attenuation values (≤10 HU) (image 1)

- Isointensity with liver on both T1- and T2-weighted MRI sequences

- Chemical shift evidence of lipid on MRI

Pheochromocytomas

- Increased attenuation on unenhanced CT (>20 HU) [33]

- Increased mass vascularity (image 2)
- High signal intensity on T2-weighted MRI (image 3)
- Cystic and hemorrhagic changes
- Variable size and may be bilateral

Adrenocortical carcinoma

- Irregular shape
- Inhomogeneous density because of central areas of low attenuation due to tumor necrosis (image 4)
- Tumor calcification
- Diameter usually >4 cm
- Unilateral location
- High unenhanced CT attenuation values (>20 HU)
- Inhomogeneous enhancement on CT with intravenous contrast
- Hypointensity compared with liver on T1-weighted MRI and high to intermediate signal intensity on T2-weighted MRI
- High standardized uptake value (SUV) on FDG-PET-CT study
- Evidence of local invasion or metastases (see "Clinical manifestations and diagnosis of adrenocortical carcinoma", section on 'Radiographic studies')

Adrenal metastases

- Irregular shape and inhomogeneous nature (image 5)
- Tendency to be bilateral
- High unenhanced CT attenuation values (>20 HU) and enhancement with intravenous contrast on CT
- Isointensity or slightly less intense than the liver on T1-weighted MRI and high to intermediate signal intensity on T2-weighted MRI (representing an increased water content)

- Elevated SUV on FDG-PET scan

Other — Adrenal cysts, adrenal hemorrhage, and myelolipoma (image 6) are usually easily characterized because of their distinctive imaging characteristics.

Fine-needle aspiration biopsy — Cytology from a specimen obtained by fine-needle aspiration (FNA) biopsy **cannot** distinguish a benign cortical adrenal mass from the less common adrenal carcinoma. It can, however, distinguish between an adrenal tumor and a metastatic tumor [34]. In a patient with a known primary malignancy elsewhere who has a newly discovered adrenal mass that has an imaging phenotype consistent with metastatic disease, performing a diagnostic CT-guided FNA biopsy may be indicated, but only after excluding pheochromocytoma with biochemical testing. Adrenal biopsy would not be needed if the patient was already known to have widespread metastatic disease [35,36].

One report, as an example, evaluated patients with known lung cancer and an adrenal mass; FNA biopsy revealed a benign adrenal lesion in two-thirds of cases [32]. When the non-adrenal cancer is occult, most adrenal masses are incidentaloma cortical adenomas (91 of 95 in one study [37]). Thus, FNA biopsy is not useful in the routine evaluation of incidentalomas in patients suspected to have small non-adrenal cancers.

Image-guided FNA biopsy is relatively safe; the complication rate was 2.8 percent in one series of 277 biopsies [38]. The risks of this procedure include adrenal and liver hematoma, abdominal pain, hematuria, pancreatitis, pneumothorax, formation of an adrenal abscess, and tumor recurrence along the needle track [38,39]. The FNA biopsy of a pheochromocytoma may result in hemorrhage and hypertensive crisis [40]. Therefore, the possibility of pheochromocytoma should always be ruled out by biochemical testing before FNA biopsy is undertaken [40-42].

EVALUATION FOR HORMONAL SECRETION

While most adrenal incidentalomas are nonfunctional, 10 to 15 percent secrete excess amounts of hormones [13,14]. The most complete analysis of this issue comes from a review of all 828 published articles on adrenal incidentalomas from 1980 to 2008 [14]. Only 20 of the 828 articles were selected as having met the strict criteria for a "true" adrenal incidentaloma; of these, only nine had adequate data on both diagnosis and follow-up. Patients who were suspected as having cancer were excluded. Among the 1800 patients in these nine series, these overall mean percentages of diagnoses were reported:

- **Malignant** – Primary adrenal carcinoma 1.9 percent, metastases 0.7 percent

- **Benign** – Nonfunctioning 89.7 percent, subclinical Cushing syndrome 6.4 percent, pheochromocytoma 3.1 percent, primary aldosteronism 0.6 percent

Three forms of adrenal hyperfunction should be considered in all patients who are diagnosed with an adrenal incidentaloma (algorithm 1):

- Subclinical glucocorticoid secretory autonomy (mild autonomous cortisol secretion or subclinical Cushing syndrome)
- Pheochromocytoma if the unenhanced CT attenuation is >10 HU
- Primary aldosteronism if the patient is hypertensive or has hypokalemia



Approach to the patient with an adrenal incidentaloma

Algorithm 1 - larger image below

Subclinical Cushing syndrome — Subclinical Cushing syndrome (or mild autonomous cortisol secretion [MACS], cortisol hypersecretion without clinical manifestations of Cushing syndrome) is the most frequent hormonal abnormality detected in patients with adrenal incidentalomas. Some adrenal incidentalomas secrete cortisol independently of corticotropin (ACTH) [43], which may have clinically important consequences [44]. Cortisol secretion can be under the control of one or more aberrant hormone receptors in patients with unilateral adenomas or incidental primary bilateral macronodular adrenal hyperplasia (PBMAH) [45,46]. (See "Cushing syndrome due to primary bilateral macronodular adrenal hyperplasia", section on 'Aberrant hormone receptors'.)

Clinical manifestations — Although these patients lack many of the usual stigmata of overt Cushing syndrome (see "Epidemiology and clinical manifestations of Cushing syndrome", section on 'Categories of clinical manifestations'), they may have one or more of the effects of continuous ACTH-independent cortisol secretion, including metabolic syndrome (hypertension, dyslipidemia, diabetes), weight gain, osteoporosis/fracture, and evidence of atherosclerosis and other cardiac anomalies [44,47-50].

- Metabolic syndrome – In a meta-analysis of 47 observational studies in 17,156 participants with adrenal incidentaloma, individuals with MACS (defined as serum cortisol >1.8 mcg/dL after a 1 mg overnight dexamethasone suppression test) exhibited a higher prevalence of diabetes (20 studies; relative risk [RR] 1.44, 95% CI 1.23-1.69), hypertension (31 studies; RR 1.24, 95% CI 1.16-1.32), and dyslipidemia (22 studies; RR 1.23, 95% CI 1.13-1.34) compared with participants with nonfunctioning adrenal adenomas [51].

- Osteoporosis/fracture – In a meta-analysis of 12 observational studies that evaluated fracture risk and bone health, MACS was associated with a 1.5- to 2-fold higher likelihood of fractures and osteoporosis/osteopenia compared with nonfunctional adrenal tumors [50]. As an example of the included studies, in a two-year longitudinal study of 103 consecutive patients with adrenal incidentaloma, the incidence of new vertebral fractures was higher in patients with MACS (48 percent) than in those without MACS (13 percent) [52].

- Cardiac anomalies – Atrial fibrillation (AF) is more common in patients with MACS when compared with those with nonsecreting adenomas. In a retrospective study of patients with MACS or nonsecreting adenomas (n = 632), the prevalence of AF was higher at baseline in the ACS patients (8.5 percent, 18 of 212) compared with the nonsecreting group (3.1 percent, 13 of 420) [53]. At the completion of the study (median follow-up of 7.7 years), the AF rate remained higher in the MACS group: 20 percent (22 of 108) versus the nonsecreting group, 12 percent (30 of 249). Given these rates, patients with MACS should be monitored for AF.

Diagnosis — Subclinical Cushing syndrome should be ruled out by obtaining a baseline serum dehydroepiandrosterone sulfate (DHEAS) and performing the 1 mg overnight dexamethasone suppression test (DST) (algorithm 1) [54]. Of note, the overnight DST should **not** be performed if the patient is thought to have a pheochromocytoma based upon the initial imaging study (unenhanced CT attenuation >10 HU). Reports of catecholaminergic crisis (some fatal) during DSTs have been described in patients with pheochromocytoma. Although most have been with high-dose DST, cases with low-dose DST have also been described [55,56].

Random, morning, or late-night serum cortisol levels are not useful for diagnosis of subclinical Cushing syndrome. In addition, most ACTH assays lack sensitivity at the lower part of the reference range and cannot be relied on to identify autonomous cortisol secretion.

- **DHEAS** – A low DHEAS reflects chronic suppression of ACTH secretion. In a study of 185 patients with adrenal incidentaloma, 29 patients (16 percent) were diagnosed with subclinical Cushing syndrome [57]. An age- and sex-specific DHEAS ratio (derived by dividing the DHEAS by the lower limit of the respective reference range for age and sex) of <1.12 was sensitive (>99 percent) and specific (91.9 percent) for the diagnosis of subclinical Cushing syndrome [57].

  In a retrospective study of 256 patients with adrenal incidentaloma and MACS, a serum DHEAS concentration <40 mcg/dL was 84 percent specific for MACS, whereas an ACTH concentration <10 pg/mL was only 75 percent specific for MACS [58]. In addition, a serum DHEAS concentration >100 mcg/dL combined with an ACTH concentration >15 pg/mL was 96 percent specific for excluding MACS [58].

- **DST** – An abnormal 1 mg overnight DST (cortisol >1.8 mcg/dL [>50 nmol/L]) is consistent with ACTH-independent autonomous cortisol production. Some centers use a higher dose of dexamethasone (eg, 2 or 3 mg rather than the standard 1 mg) to reduce false-positive results [59]. Positive findings on the initial DST should be further evaluated with 24-hour urinary free cortisol, serum ACTH concentration, and a high-dose (8 mg) overnight DST. **Clinically significant** glucocorticoid secretory autonomy is confirmed by a post-overnight 8 mg DST 8 AM serum cortisol concentration >1.8 mcg/dL (>50 nmol/L). (See "Establishing the diagnosis of Cushing syndrome".)

  A study of the two-day, low-dose DST [60] showed a gradation between subnormal and complete suppression of serum cortisol concentrations in 57 patients with adrenal incidentalomas (21 percent had undetectable serum levels of cortisol, 67 percent had values between 1 and 5 mcg/dL, and 12 percent had values between 5.0 and 7.8 mcg/dL). Thus, the question for the clinician when glucocorticoid secretory activity is found is whether the cortical adenoma has **clinically significant** glucocorticoid secretory activity.

Bilateral adrenal masses and subclinical Cushing syndrome — This clinical scenario is being increasingly recognized. When the bilateral adrenal masses are consistent with solitary bilateral adenomas on cross-sectional computed imaging, consideration should be given to adrenal venous sampling [61-63] (see "Diagnosis of primary aldosteronism", section on 'Adrenal vein sampling'). In this setting, adrenal venous sampling is performed without cosyntropin administration, and successful adrenal vein catheterization is confirmed with either catecholamine or metanephrine gradients between the adrenal veins and the inferior vena cava [63].

In a study of 14 patients with bilateral adrenal nodules and ACTH-independent subclinical or clinical Cushing syndrome, 10 had bilateral and 4 had unilateral cortisol overproduction [62]. In patients where the computed images of the primary adrenal glands are consistent with PBMAH (image 7), adrenal vein sampling is **not** needed, because this is a bilateral adrenal disorder. (See "Cushing syndrome due to primary bilateral macronodular adrenal hyperplasia", section on 'Initial evaluation'.)

Pheochromocytoma — Approximately 3 percent of adrenal incidentalomas prove to be pheochromocytomas [14]. In the past, it was thought that all patients with pheochromocytoma are symptomatic. However, with widespread use of computed imaging, pheochromocytomas are being discovered in the presymptomatic stage [64,65]. In a study of 271 consecutive patients with pheochromocytoma treated from 2005 to 2016, 61 percent were discovered as an incidental finding on cross-section imaging, 27 percent due to pheochromocytoma-related symptoms, and

12 percent due to genetic variant-based testing [66]. (See "Clinical presentation and diagnosis of pheochromocytoma", section on 'Approach to initial evaluation'.)

Biochemical testing for pheochromocytoma should be performed if the unenhanced CT attenuation is ≥10 HU, but not if it is <10 HU (algorithm 1) [33]. (See "Clinical presentation and diagnosis of pheochromocytoma", section on 'Imaging'.)

Small pheochromocytomas (eg, <1.5 cm) may have normal biochemical testing (image 8). Pheochromocytomas need a critical mass before they can become biochemically detectable. Surgical resection of apparent nonfunctioning lipid-poor and vascular adrenal masses should be considered (algorithm 1).

Aldosteronomas — Aldosteronomas are rare (less than 1 percent) causes of an adrenal incidentaloma. However, because the majority of patients with primary aldosteronism are not hypokalemic, all patients with hypertension and an adrenal incidentaloma should be evaluated by measurements of plasma aldosterone concentration and plasma renin activity [1,2]. In addition, patients who are normotensive but have spontaneous hypokalemia should also be tested for primary aldosteronism (algorithm 1). (See "Diagnosis of primary aldosteronism" and "Pathophysiology and clinical features of primary aldosteronism".)

Confirmatory testing — The diagnosis and confirmation of clinically important subclinical Cushing syndrome is described above (see 'Subclinical Cushing syndrome' above). If there is biochemical evidence of either a pheochromocytoma or aldosterone-secreting adenoma on initial testing, confirmatory testing is required before treatment is considered. Confirmatory testing for these disorders is described elsewhere. (See "Clinical presentation and diagnosis of pheochromocytoma", section on 'Indeterminate case-detection test' and "Diagnosis of primary aldosteronism", section on 'Aldosterone suppression testing'.)

MANAGEMENT

Our approach to management is largely consistent with guidelines from the American Association of Endocrine Surgeons [67].

Unilateral adrenal masses

- **Pheochromocytoma and adrenocortical cancer** – All patients with documented pheochromocytoma and adrenocortical cancer should undergo prompt surgical intervention because untreated pheochromocytoma may result in significant cardiovascular complications. Alpha-adrenergic blockade should be given before patients undergo adrenalectomy. (See "Treatment of pheochromocytoma in adults".)

Patients with adrenocortical cancer or lesions suspicious for adrenocortical cancer should also undergo prompt adrenalectomy as their disease may progress rapidly. (See "Treatment of adrenocortical carcinoma".)

- **Aldosterone-producing adenomas** – Patients with aldosterone-producing adenomas should be offered surgery to cure aldosterone excess. (See "Treatment of primary aldosteronism".)

- **Subclinical Cushing syndrome** – Should all patients with this diagnosis undergo unilateral adrenalectomy? In the absence of well-designed prospective, randomized trials, it is reasonable to consider younger patients as candidates for adrenalectomy. Patients who have disorders potentially attributable to autonomous glucocorticoid secretion (eg, recent onset of hypertension, diabetes, obesity, and/or low bone mass) with well-documented glucocorticoid secretory autonomy (ie, suppressed dehydroepiandrosterone sulfate [DHEAS], failure to suppress cortisol normally on 1 mg overnight dexamethasone test [DST], low serum corticotropin [ACTH] concentration, lack of suppression to high-dose (8 mg) overnight DST [8 AM serum cortisol >1.8 mcg/dL]) are also candidates for adrenalectomy.

  In a meta-analysis of 47 studies in participants with adrenal incidentaloma, participants with subclinical Cushing syndrome who underwent adrenalectomy showed greater improvement in cardiometabolic parameters compared with those who did not undergo surgery (11 studies) [51]; however, these data were predominantly observational.

  If adrenalectomy is performed, a postoperative ACTH (cosyntropin) stimulation test should be done to evaluate adrenocortical function [68] (see "Diagnosis of adrenal insufficiency in adults", section on 'ACTH stimulation tests'). If the test demonstrates inadequate adrenocortical function (or is not performed), perioperative glucocorticoid coverage should be administered because of the risk of adrenal insufficiency, hemodynamic crisis, and death. Patients with evidence of adrenal insufficiency should be discharged on glucocorticoid replacement and monitored for recovery of the hypothalamic-pituitary-adrenal axis [69]. Weight loss, improvement in hypertension and/or glycemic management, and normalization of markers of bone turnover are frequently found following unilateral adrenalectomy in patients with subclinical Cushing syndrome [70-72].

- **Lipid-poor adrenal masses** – Adrenal masses with either suspicious imaging phenotype or size larger than 4 cm should be considered for resection because a substantial fraction will be adrenocortical carcinomas [2,17]. The clinical scenario and patient age frequently guide the management decisions in patients who have adrenal incidentalomas that fall on either side of the 4 cm diameter cutoff. As an example, most clinicians would advise resecting a lipid-poor (29 HU) 3.2 cm adrenal incidentaloma in a 23-year-old woman, whereas most clinicians would choose serial imaging follow-up in an 83-year-old woman with a lipid-rich (9 HU) 4.7 cm

adrenal incidentaloma. Before surgery, all patients should undergo appropriate testing for functional tumors. (See 'Evaluation for hormonal secretion' above.)

- **Adrenal myelolipoma** – This is a benign tumor composed of mature fat and interspersed hematopoietic elements that resemble bone marrow. On computed imaging, the presence of large amounts of macroscopic fat in an adrenal mass is diagnostic of a myelolipoma (image 6) [73]. Although adrenal myelolipomas may grow over time, they can usually be followed without surgical excision. However, when larger than 6 cm in diameter or when causing local mass-effect symptoms, surgical removal should be considered. When adrenal myelolipomas are bilateral, the clinician should consider the diagnosis of congenital adrenal hyperplasia [74].

Bilateral adrenal masses — The management of bilateral adrenal masses is different from that for unilateral masses. As an example, in cases of primary bilateral macronodular adrenal hyperplasia (PBMAH) (image 7), size is not an indication for surgery, whereas the degree of cortisol secretory autonomy should guide surgical decision-making. Patients with PBMAH and clinical Cushing syndrome usually are best treated with bilateral adrenalectomy, whereas patients with PBMAH and subclinical Cushing syndrome may be managed by resecting the larger adrenal gland.

Surgical management should be guided by the findings on adrenal venous sampling in patients with ACTH-independent Cushing syndrome or subclinical Cushing syndrome in the setting of solitary bilateral adrenal adenomas [61-63].

Adrenalectomy — Adrenalectomy for patients with aldosteronomas, pheochromocytoma, cortisol-secreting tumors, and adrenal incidentalomas is safe and effective [75]. An adrenalectomy may be done laparoscopically, endoscopically via the posterior approach, or as an open procedure. Laparoscopic adrenalectomy, compared with open adrenalectomy, is associated with less pain, shorter hospitalization time, less blood loss, and faster recovery [76]. The laparoscopic approach is used for most adrenal masses [67].

In patients with known or suspected adrenal carcinoma, the laparoscopic approach should only be considered if the adrenal mass is <6 cm and does not appear to be locally invasive [77-79]. An open adrenalectomy is recommended for all large (>10 cm) adrenal masses, including those with benign imaging features, as the adrenal mass may be diagnosed as malignant on a definitive histologic review [77,80-83]. (See 'Imaging phenotype' above and "Adrenalectomy techniques", section on 'Approach by indication'.)

Monitoring when surgery not performed

- **Radiologic monitoring**
  - **Frequency of imaging** – For incidentalomas with a benign appearance on imaging, we repeat imaging after 12 months to reconfirm the initial diagnosis of a benign adrenal mass [7]. The decision to obtain additional images (eg, at 3, 6, 12, and 24 months after the initial image) and the type of image obtained (eg, CT or MRI) should be guided by the individual clinical circumstance, imaging phenotype, and clinical judgment, as well as consideration of radiation exposure from CT (algorithm 1) [14].

    Some expert guidelines state that repeat imaging is not required for tumors with a benign imaging appearance [67,84]. However, unenhanced CT attenuation values are not uniformly available, and imaging reports that solely indicate "adenoma" may offer inappropriate reassurance that the mass is benign [85]. Thus, a single repeat image is reasonable in patients who have no history of malignancy and who have small (less than 2 cm), uniform, low unenhanced CT attenuation cortical nodules (ie, benign imaging phenotype). No prospective studies have assessed the optimal frequency and duration of follow-up for adrenal incidentalomas. (See "Radiation-related risks of imaging", section on 'Clinical decision-making and informing patients'.)

  - **Interim growth** – Most experts would consider resecting any tumor that enlarges by more than 1 cm in diameter during the follow-up period (algorithm 1). However, most adrenal masses that grow are not malignant. Nonetheless, surgical removal should be considered for masses ≥4 cm to avoid missing adrenal carcinomas, particularly in younger patients. (See 'Size' above.)

- **Biochemical monitoring** – The observation that autonomous function (glucocorticoid hypersecretion) not present at baseline may be detected at follow-up testing [86-88] has led to the recommendation for repeating the baseline DHEAS measurement and the overnight DST annually for four years in cases where initial evaluation is negative [1,87,88]; however, the yield and cost effectiveness of such testing is also unknown [7,14].

SOCIETY GUIDELINE LINKS

Links to society and government-sponsored guidelines from selected countries and regions around the world are provided separately. (See "Society guideline links: Diagnosis and treatment of Cushing syndrome" and "Society guideline links: Adrenal incidentaloma".)

INFORMATION FOR PATIENTS

UpToDate offers two types of patient education materials, "The Basics" and "Beyond the Basics." The Basics patient education pieces are written in plain language, at the 5th to 6th grade reading level, and they answer the four or five key questions a patient might have about a given condition. These articles are best for patients who want a general overview and who prefer short, easy-to-read materials. Beyond the Basics patient education pieces are longer, more sophisticated, and more detailed. These articles are written at the 10th to 12th grade reading level and are best for patients who want in-depth information and are comfortable with some medical jargon.

Here are the patient education articles that are relevant to this topic. We encourage you to print or e-mail these topics to your patients. (You can also locate patient education articles on a variety of subjects by searching on "patient info" and the keyword(s) of interest.)

- Basics topic (see "Patient education: Adrenal cancer (The Basics)")

SUMMARY AND RECOMMENDATIONS

- **Adrenal incidentaloma definition** – An adrenal incidentaloma is a mass lesion greater than 1 cm in diameter, serendipitously discovered by radiologic examination. This entity is the result of technological advances in imaging such as CT and MRI. (See 'Introduction' above.)

- **Imaging phenotype** – All patients with adrenal incidentalomas should be evaluated for the possibility of malignancy. The size and imaging characteristics ("imaging phenotype") of the mass may help determine whether the tumor is benign or malignant. (See 'Evaluation for malignancy' above.)

  - **Benign cortical adenoma** – A homogeneous adrenal mass <4 cm in diameter, with a smooth border, and an attenuation value <10 Hounsfield unit (HU) on unenhanced CT is very likely to be a benign cortical adenoma. (See 'CT scan' above.)

  - **Adrenal carcinoma or metastases** – The imaging characteristics that suggest adrenal carcinoma or metastases include irregular shape, inhomogeneous density, high unenhanced CT attenuation values (>20 HU), diameter >4 cm, and tumor calcification. Other characteristics are described above. (See 'Adrenocortical carcinoma' above.)

- **Evaluation for hormonal secretion** – All patients with adrenal incidentalomas should be evaluated for the possibility of subclinical hormonal hyperfunction.

  - **Pheochromocytoma** – Pheochromocytoma should be excluded in all patients with adrenal incidentalomas with unenhanced CT attenuation >10 HU by measuring 24-hour urinary

fractionated metanephrines and catecholamines or plasma fractionated metanephrines. (See 'Pheochromocytoma' above.)

- **Subclinical Cushing syndrome** – Subclinical Cushing syndrome should be ruled out by measuring baseline dehydroepiandrosterone sulfate (DHEAS) and performing the 1 mg overnight dexamethasone suppression test (DST). To detect **clinically significant** glucocorticoid secretory autonomy, the post-overnight 1 mg DST 8 AM serum cortisol concentration cutoff is >1.8 mcg/dL (>50 nmol/L). An abnormal 1 mg overnight DST is consistent with corticotropin (ACTH)-independent cortisol production, a finding that should be confirmed with 24-hour urinary free cortisol, serum ACTH concentration, and a high-dose (8 mg) overnight DST. (See 'Subclinical Cushing syndrome' above.)

- **Primary aldosteronism (selected patients)** – If the adrenal incidentaloma patient has hypertension or hypokalemia, a plasma aldosterone level and plasma renin activity should be measured to screen for primary aldosteronism. (See 'Aldosteronomas' above.)

- **Management**

  - **Pheochromocytoma** – We recommend surgery for all patients with biochemical documentation of pheochromocytoma. The preoperative management and surgical approach of patients with pheochromocytoma are reviewed elsewhere. (See "Treatment of pheochromocytoma in adults".)

  - **Subclinical Cushing syndrome** – We suggest surgical resection for patients with subclinical Cushing syndrome who are good surgical candidates and who have disorders potentially attributable to excess glucocorticoid secretion (eg, recent onset of hypertension, diabetes, obesity, and/or low bone mass) (**Grade 2C**). (See 'Unilateral adrenal masses' above.)

  - **Suspected metastatic disease** – In a patient with a known primary malignancy elsewhere who has a newly discovered adrenal mass that has an imaging phenotype consistent with metastatic disease, performing a diagnostic CT-guided fine-needle aspiration (FNA) biopsy may be indicated, but **only** after excluding pheochromocytoma with biochemical testing. Adrenal biopsy is not needed if the patient is already known to have widespread metastatic disease. (See 'Fine-needle aspiration biopsy' above.)

  - **Suspected carcinoma** – We suggest excision of a tumor if the initial imaging phenotype is suspicious (**Grade 2C**). (See 'Unilateral adrenal masses' above.)

  - **Masses >4 cm** – In patients with adrenal masses greater than 4 cm in diameter, we consider surgical resection. However, the clinical scenario, imaging characteristics, and patient age frequently guide the management decisions in patients who have adrenal incidentalomas

that fall on either side of the 4 cm diameter cutoff. (See 'Size' above and 'Unilateral adrenal masses' above.)

- **Adrenalectomy** – The laparoscopic approach is used for most adrenal masses. In patients with known or suspected adrenal carcinoma, the laparoscopic approach should only be considered if the adrenal mass is <6 cm and does not appear to be locally invasive. For all adrenal masses larger than 10 cm, including those masses with benign imaging phenotypes, we suggest an open adrenalectomy rather than a laparoscopic procedure (**Grade 2C**). (See 'Adrenalectomy' above.)

- **Monitoring when surgery not performed**

  - **Repeat imaging** – For incidentalomas with a benign appearance on imaging, we perform a repeat imaging study at 12 months after initial discovery. The rationale is that many malignant lesions will grow in this interval, leading to earlier intervention. Whether to obtain additional images (eg, at 6, 12, and 24 months after initial discovery) and the type of image obtained (eg, CT, MRI, or ultrasound) should be guided by clinical judgment and imaging phenotype. The yield and cost-effectiveness of such a strategy are not known. (See 'Monitoring when surgery not performed' above.)

  - **Tumors with interim growth** – We suggest removal of any tumor that enlarges by more than 1 cm in diameter during the follow-up period (**Grade 2C**). (See 'Monitoring when surgery not performed' above.)

  - **Biochemical monitoring** – We suggest that baseline DHEAS and an overnight DST be repeated annually for four years in cases where initial evaluation is negative, although the yield and cost effectiveness of such testing is also unknown. Autonomous function (glucocorticoid hypersecretion) not present at baseline may be detected at follow-up testing. (See 'Monitoring when surgery not performed' above.)

ACKNOWLEDGMENTS

The views expressed in this topic are those of the author(s) and do not reflect the official views or policy of the United States Government or its components.

The UpToDate editorial staff acknowledges Norman M Kaplan, MD, who contributed to earlier versions of this topic review.

Use of UpToDate is subject to the Terms of Use.

REFERENCES

1. Young WF Jr. Clinical practice. The incidentally discovered adrenal mass. N Engl J Med 2007; 356:601.
2. Grumbach MM, Biller BM, Braunstein GD, et al. Management of the clinically inapparent adrenal mass ("incidentaloma"). Ann Intern Med 2003; 138:424.
3. Herrera MF, Grant CS, van Heerden JA, et al. Incidentally discovered adrenal tumors: an institutional perspective. Surgery 1991; 110:1014.
4. Bovio S, Cataldi A, Reimondo G, et al. Prevalence of adrenal incidentaloma in a contemporary computerized tomography series. J Endocrinol Invest 2006; 29:298.
5. Jing Y, Hu J, Luo R, et al. Prevalence and Characteristics of Adrenal Tumors in an Unselected Screening Population : A Cross-Sectional Study. Ann Intern Med 2022; 175:1383.
6. Reimondo G, Castellano E, Grosso M, et al. Adrenal Incidentalomas are Tied to Increased Risk of Diabetes: Findings from a Prospective Study. J Clin Endocrinol Metab 2020; 105.
7. Terzolo M, Stigliano A, Chiodini I, et al. AME position statement on adrenal incidentaloma. Eur J Endocrinol 2011; 164:851.
8. Hedeland H, Ostberg G, Hökfelt B. On the prevalence of adrenocortical adenomas in an autopsy material in relation to hypertension and diabetes. Acta Med Scand 1968; 184:211.
9. Angeli A, Osella G, Alì A, Terzolo M. Adrenal incidentaloma: an overview of clinical and epidemiological data from the National Italian Study Group. Horm Res 1997; 47:279.
10. Barzon L, Scaroni C, Sonino N, et al. Incidentally discovered adrenal tumors: endocrine and scintigraphic correlates. J Clin Endocrinol Metab 1998; 83:55.
11. Kasperlik-Zeluska AA, Rosłonowska E, Słowinska-Srzednicka J, et al. Incidentally discovered adrenal mass (incidentaloma): investigation and management of 208 patients. Clin Endocrinol (Oxf) 1997; 46:29.
12. Young WF Jr. Management approaches to adrenal incidentalomas. A view from Rochester, Minnesota. Endocrinol Metab Clin North Am 2000; 29:159.
13. Mantero F, Terzolo M, Arnaldi G, et al. A survey on adrenal incidentaloma in Italy. Study Group on Adrenal Tumors of the Italian Society of Endocrinology. J Clin Endocrinol Metab 2000; 85:637.
14. Cawood TJ, Hunt PJ, O'Shea D, et al. Recommended evaluation of adrenal incidentalomas is costly, has high false-positive rates and confers a risk of fatal cancer that is similar to the risk of the adrenal lesion becoming malignant; time for a rethink? Eur J Endocrinol 2009; 161:513.

15. Nieman LK. Approach to the patient with an adrenal incidentaloma. J Clin Endocrinol Metab 2010; 95:4106.
16. Wilson MP, Randhawa S, Bao B, et al. Impact of Size Thresholds on the Diagnosis of Incidental Adrenal Lesions: A Systematic Review and Meta-Analysis. J Am Coll Radiol 2024; 21:107.
17. Henley DJ, van Heerden JA, Grant CS, et al. Adrenal cortical carcinoma--a continuing challenge. Surgery 1983; 94:926.
18. Iñiguez-Ariza NM, Kohlenberg JD, Delivanis DA, et al. Clinical, Biochemical, and Radiological Characteristics of a Single-Center Retrospective Cohort of 705 Large Adrenal Tumors. Mayo Clin Proc Innov Qual Outcomes 2018; 2:30.
19. Sherlock M, Scarsbrook A, Abbas A, et al. Adrenal Incidentaloma. Endocr Rev 2020; 41:775.
20. Fassnacht M, Tsagarakis S, Terzolo M, et al. European Society of Endocrinology clinical practice guidelines on the management of adrenal incidentalomas, in collaboration with the European Network for the Study of Adrenal Tumors. Eur J Endocrinol 2023; 189:G1.
21. Hamrahian AH, Ioachimescu AG, Remer EM, et al. Clinical utility of noncontrast computed tomography attenuation value (hounsfield units) to differentiate adrenal adenomas/hyperplasias from nonadenomas: Cleveland Clinic experience. J Clin Endocrinol Metab 2005; 90:871.
22. Delivanis DA, Bancos I, Atwell TD, et al. Diagnostic performance of unenhanced computed tomography and 18 F-fluorodeoxyglucose positron emission tomography in indeterminate adrenal tumours. Clin Endocrinol (Oxf) 2018; 88:30.
23. Korobkin M, Brodeur FJ, Francis IR, et al. CT time-attenuation washout curves of adrenal adenomas and nonadenomas. AJR Am J Roentgenol 1998; 170:747.
24. Szolar DH, Korobkin M, Reittner P, et al. Adrenocortical carcinomas and adrenal pheochromocytomas: mass and enhancement loss evaluation at delayed contrast-enhanced CT. Radiology 2005; 234:479.
25. Peña CS, Boland GW, Hahn PF, et al. Characterization of indeterminate (lipid-poor) adrenal masses: use of washout characteristics at contrast-enhanced CT. Radiology 2000; 217:798.
26. Corwin MT, Badawy M, Caoili EM, et al. Incidental Adrenal Nodules in Patients Without Known Malignancy: Prevalence of Malignancy and Utility of Washout CT for Characterization-A Multiinstitutional Study. AJR Am J Roentgenol 2022; 219:804.
27. Platzek I, Sieron D, Plodeck V, et al. Chemical shift imaging for evaluation of adrenal masses: a systematic review and meta-analysis. Eur Radiol 2019; 29:806.

28. Groussin L, Bonardel G, Silvéra S, et al. 18F-Fluorodeoxyglucose positron emission tomography for the diagnosis of adrenocortical tumors: a prospective study in 77 operated patients. J Clin Endocrinol Metab 2009; 94:1713.
29. Guerin C, Pattou F, Brunaud L, et al. Performance of 18F-FDG PET/CT in the Characterization of Adrenal Masses in Noncancer Patients: A Prospective Study. J Clin Endocrinol Metab 2017; 102:2465.
30. Schaafsma M, Berends AMA, Links TP, et al. The Diagnostic Value of 18F-FDG PET/CT Scan in Characterizing Adrenal Tumors. J Clin Endocrinol Metab 2023; 108:2435.
31. Hennings J, Hellman P, Ahlström H, Sundin A. Computed tomography, magnetic resonance imaging and 11C-metomidate positron emission tomography for evaluation of adrenal incidentalomas. Eur J Radiol 2009; 69:314.
32. Dunnick NR, Korobkin M, Francis I. Adrenal radiology: distinguishing benign from malignant adrenal masses. AJR Am J Roentgenol 1996; 167:861.
33. Canu L, Van Hemert JAW, Kerstens MN, et al. CT Characteristics of Pheochromocytoma: Relevance for the Evaluation of Adrenal Incidentaloma. J Clin Endocrinol Metab 2019; 104:312.
34. Mazzaglia PJ, Monchik JM. Limited value of adrenal biopsy in the evaluation of adrenal neoplasm: a decade of experience. Arch Surg 2009; 144:465.
35. Cook DM, Loriaux DL. The incidental adrenal mass. Am J Med 1996; 101:88.
36. Jhala NC, Jhala D, Eloubeidi MA, et al. Endoscopic ultrasound-guided fine-needle aspiration biopsy of the adrenal glands: analysis of 24 patients. Cancer 2004; 102:308.
37. Lee JE, Evans DB, Hickey RC, et al. Unknown primary cancer presenting as an adrenal mass: frequency and implications for diagnostic evaluation of adrenal incidentalomas. Surgery 1998; 124:1115.
38. Welch TJ, Sheedy PF 2nd, Stephens DH, et al. Percutaneous adrenal biopsy: review of a 10-year experience. Radiology 1994; 193:341.
39. Arellano RS, Harisinghani MG, Gervais DA, et al. Image-guided percutaneous biopsy of the adrenal gland: review of indications, technique, and complications. Curr Probl Diagn Radiol 2003; 32:3.
40. Vanderveen KA, Thompson SM, Callstrom MR, et al. Biopsy of pheochromocytomas and paragangliomas: potential for disaster. Surgery 2009; 146:1158.
41. Casola G, Nicolet V, vanSonnenberg E, et al. Unsuspected pheochromocytoma: risk of blood-pressure alterations during percutaneous adrenal biopsy. Radiology 1986; 159:733.

42. McCorkell SJ, Niles NL. Fine-needle aspiration of catecholamine-producing adrenal masses: a possibly fatal mistake. AJR Am J Roentgenol 1985; 145:113.

43. Tauchmanovà L, Rossi R, Biondi B, et al. Patients with subclinical Cushing's syndrome due to adrenal adenoma have increased cardiovascular risk. J Clin Endocrinol Metab 2002; 87:4872.

44. Prete A, Subramanian A, Bancos I, et al. Cardiometabolic Disease Burden and Steroid Excretion in Benign Adrenal Tumors : A Cross-Sectional Multicenter Study. Ann Intern Med 2022; 175:325.

45. Reznik Y, Lefebvre H, Rohmer V, et al. Aberrant adrenal sensitivity to multiple ligands in unilateral incidentaloma with subclinical autonomous cortisol hypersecretion: a prospective clinical study. Clin Endocrinol (Oxf) 2004; 61:311.

46. Hsiao HP, Kirschner LS, Bourdeau I, et al. Clinical and genetic heterogeneity, overlap with other tumor syndromes, and atypical glucocorticoid hormone secretion in adrenocorticotropin-independent macronodular adrenal hyperplasia compared with other adrenocortical tumors. J Clin Endocrinol Metab 2009; 94:2930.

47. Chiodini I, Morelli V, Masserini B, et al. Bone mineral density, prevalence of vertebral fractures, and bone quality in patients with adrenal incidentalomas with and without subclinical hypercortisolism: an Italian multicenter study. J Clin Endocrinol Metab 2009; 94:3207.

48. Sereg M, Szappanos A, Toke J, et al. Atherosclerotic risk factors and complications in patients with non-functioning adrenal adenomas treated with or without adrenalectomy: a long-term follow-up study. Eur J Endocrinol 2009; 160:647.

49. Morelli V, Reimondo G, Giordano R, et al. Long-term follow-up in adrenal incidentalomas: an Italian multicenter study. J Clin Endocrinol Metab 2014; 99:827.

50. Pal R, Banerjee M, Prasad TN, et al. Fracture risk and bone health in adrenal adenomas with mild autonomous cortisol secretion/subclinical hypercortisolism: a systematic review, meta-analysis and meta-regression. J Bone Miner Res 2024; 39:885.

51. Pelsma ICM, Fassnacht M, Tsagarakis S, et al. Comorbidities in mild autonomous cortisol secretion and the effect of treatment: systematic review and meta-analysis. Eur J Endocrinol 2023; 189:S88.

52. Morelli V, Eller-Vainicher C, Salcuni AS, et al. Risk of new vertebral fractures in patients with adrenal incidentaloma with and without subclinical hypercortisolism: a multicenter longitudinal study. J Bone Miner Res 2011; 26:1816.

53. Di Dalmazi G, Vicennati V, Pizzi C, et al. Prevalence and Incidence of Atrial Fibrillation in a Large Cohort of Adrenal Incidentalomas: A Long-Term Study. J Clin Endocrinol Metab 2020; 105.

54. Fassnacht M, Arlt W, Bancos I, et al. Management of adrenal incidentalomas: European Society of Endocrinology Clinical Practice Guideline in collaboration with the European Network for the Study of Adrenal Tumors. Eur J Endocrinol 2016; 175:G1.

55. Barrett C, van Uum SH, Lenders JW. Risk of catecholaminergic crisis following glucocorticoid administration in patients with an adrenal mass: a literature review. Clin Endocrinol (Oxf) 2015; 83:622.

56. Rosas AL, Kasperlik-Zaluska AA, Papierska L, et al. Pheochromocytoma crisis induced by glucocorticoids: a report of four cases and review of the literature. Eur J Endocrinol 2008; 158:423.

57. Dennedy MC, Annamalai AK, Prankerd-Smith O, et al. Low DHEAS: A Sensitive and Specific Test for the Detection of Subclinical Hypercortisolism in Adrenal Incidentalomas. J Clin Endocrinol Metab 2017; 102:786.

58. Carafone LE, Zhang CD, Li D, et al. Diagnostic Accuracy of Dehydroepiandrosterone Sulfate and Corticotropin in Autonomous Cortisol Secretion. Biomedicines 2021; 9.

59. Reincke M. Subclinical Cushing's syndrome. Endocrinol Metab Clin North Am 2000; 29:43.

60. Tsagarakis S, Kokkoris P, Roboti C, et al. The low-dose dexamethasone suppression test in patients with adrenal incidentalomas: comparisons with clinically euadrenal subjects and patients with Cushing's syndrome. Clin Endocrinol (Oxf) 1998; 48:627.

61. Young WF Jr, du Plessis H, Thompson GB, et al. The clinical conundrum of corticotropin-independent autonomous cortisol secretion in patients with bilateral adrenal masses. World J Surg 2008; 32:856.

62. Ueland GÅ, Methlie P, Jøssang DE, et al. Adrenal Venous Sampling for Assessment of Autonomous Cortisol Secretion. J Clin Endocrinol Metab 2018; 103:4553.

63. Johnson PC, Thompson SM, Adamo D, et al. Adrenal venous sampling for lateralization of cortisol hypersecretion in patients with bilateral adrenal masses. Clin Endocrinol (Oxf) 2023; 98:177.

64. Motta-Ramirez GA, Remer EM, Herts BR, et al. Comparison of CT findings in symptomatic and incidentally discovered pheochromocytomas. AJR Am J Roentgenol 2005; 185:684.

65. Kopetschke R, Slisko M, Kilisli A, et al. Frequent incidental discovery of phaeochromocytoma: data from a German cohort of 201 phaeochromocytoma. Eur J Endocrinol 2009; 161:355.

66. Gruber LM, Hartman RP, Thompson GB, et al. Pheochromocytoma Characteristics and Behavior Differ Depending on Method of Discovery. J Clin Endocrinol Metab 2019; 104:1386.

67. Yip L, Duh QY, Wachtel H, et al. American Association of Endocrine Surgeons Guidelines for Adrenalectomy: Executive Summary. JAMA Surg 2022; 157:870.

68. Johnson S, Zhang CD, Hangge PT, et al. Cosyntropin Stimulation Testing is More Selective than Postoperative Day 1 Basal Cortisol for Diagnosing Secondary Adrenal Insufficiency After Unilateral Adrenalectomy. Ann Surg Oncol 2024; 31:6883.
69. Hurtado MD, Cortes T, Natt N, et al. Extensive clinical experience: Hypothalamic-pituitary-adrenal axis recovery after adrenalectomy for corticotropin-independent cortisol excess. Clin Endocrinol (Oxf) 2018; 89:721.
70. Toniato A, Merante-Boschin I, Opocher G, et al. Surgical versus conservative management for subclinical Cushing syndrome in adrenal incidentalomas: a prospective randomized study. Ann Surg 2009; 249:388.
71. Mantero F, Arnaldi G. Investigation protocol: adrenal enlargement. Clin Endocrinol (Oxf) 1999; 50:141.
72. Emral R, Uysal AR, Asik M, et al. Prevalence of subclinical Cushing's syndrome in 70 patients with adrenal incidentaloma: clinical, biochemical and surgical outcomes. Endocr J 2003; 50:399.
73. Craig WD, Fanburg-Smith JC, Henry LR, et al. Fat-containing lesions of the retroperitoneum: radiologic-pathologic correlation. Radiographics 2009; 29:261.
74. McGeoch SC, Olson S, Krukowski ZH, Bevan JS. Giant bilateral myelolipomas in a man with congenital adrenal hyperplasia. J Clin Endocrinol Metab 2012; 97:343.
75. Liao CH, Lai MK, Li HY, et al. Laparoscopic adrenalectomy using needlescopic instruments for adrenal tumors less than 5cm in 112 cases. Eur Urol 2008; 54:640.
76. Thompson GB, Grant CS, van Heerden JA, et al. Laparoscopic versus open posterior adrenalectomy: a case-control study of 100 patients. Surgery 1997; 122:1132.
77. Gonzalez RJ, Shapiro S, Sarlis N, et al. Laparoscopic resection of adrenal cortical carcinoma: a cautionary note. Surgery 2005; 138:1078.
78. Saunders BD, Doherty GM. Laparoscopic adrenalectomy for malignant disease. Lancet Oncol 2004; 5:718.
79. Fassnacht M, Dekkers O, Else T, et al. European Society of Endocrinology Clinical Practice Guidelines on the Management of Adrenocortical Carcinoma in Adults, in collaboration with the European Network for the Study of Adrenal Tumors. Eur J Endocrinol 2018.
80. Porpiglia F, Fiori C, Daffara F, et al. Retrospective evaluation of the outcome of open versus laparoscopic adrenalectomy for stage I and II adrenocortical cancer. Eur Urol 2010; 57:873.
81. Brix D, Allolio B, Fenske W, et al. Laparoscopic versus open adrenalectomy for adrenocortical carcinoma: surgical and oncologic outcome in 152 patients. Eur Urol 2010; 58:609.

82. Leboulleux S, Deandreis D, Al Ghuzlan A, et al. Adrenocortical carcinoma: is the surgical approach a risk factor of peritoneal carcinomatosis? Eur J Endocrinol 2010; 162:1147.
83. Miller BS, Ammori JB, Gauger PG, et al. Laparoscopic resection is inappropriate in patients with known or suspected adrenocortical carcinoma. World J Surg 2010; 34:1380.
84. Rowe NE, Kumar RM, Schieda N, et al. Canadian Urological Association guideline: Diagnosis, management, and followup of the incidentally discovered adrenal mass. Can Urol Assoc J 2023; 17:12.
85. Angelousi A, Jouinot A, Bourgioti C, et al. Transformation of a Benign Adrenocortical Adenoma to a Metastatic Adrenocortical Carcinoma Is Rare But It Happens. JCEM Case Rep 2024; 2:luae131.
86. Libè R, Dall'Asta C, Barbetta L, et al. Long-term follow-up study of patients with adrenal incidentalomas. Eur J Endocrinol 2002; 147:489.
87. Bülow B, Jansson S, Juhlin C, et al. Adrenal incidentaloma - follow-up results from a Swedish prospective study. Eur J Endocrinol 2006; 154:419.
88. Barzon L, Scaroni C, Sonino N, et al. Risk factors and long-term follow-up of adrenal incidentalomas. J Clin Endocrinol Metab 1999; 84:520.

Topic 153 Version 39.0

GRAPHICS

Image 1: **Lipid-rich benign adrenal adenoma**

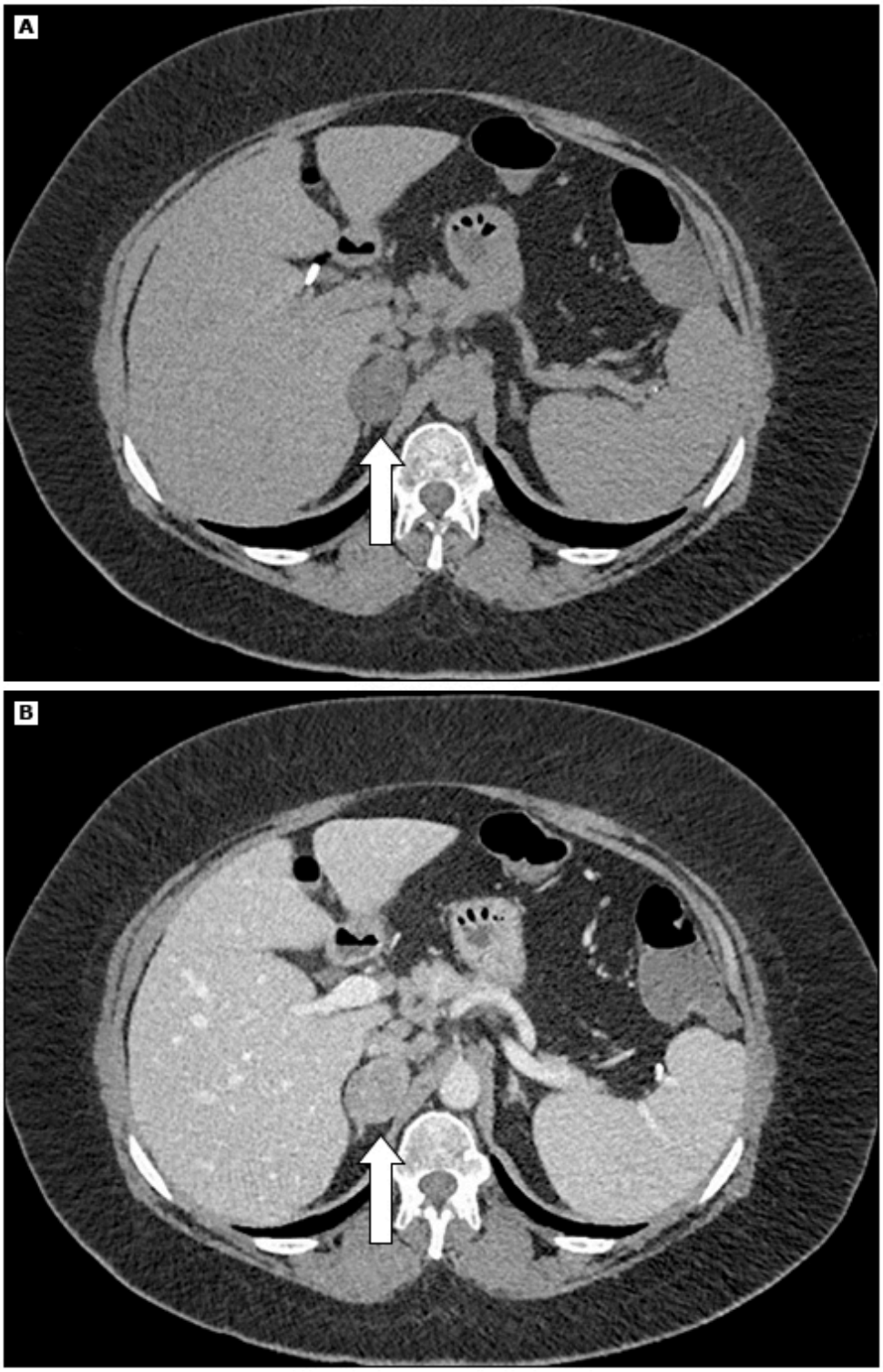

Unenhanced (A) and enhanced (B) axial CT images of an incidentally discovered 2.8 × 3.5 cm right adrenal mass (arrows). On the unenhanced image, the CT attenuation was 5 HU and diagnostic of a lipid-rich adrenal mass. With contrast administration, the adrenal mass was shown to be not vascular (B), enhanced homogenously, and had rapid contrast washout (>50% at 10 minutes).

CT: computed tomography; HU: Houndsfield units.

Courtesy of William F Young, Jr, MD.

Graphic 52211 Version 4.0

Image 2: **Biochemically detectable pheochromocytoma**

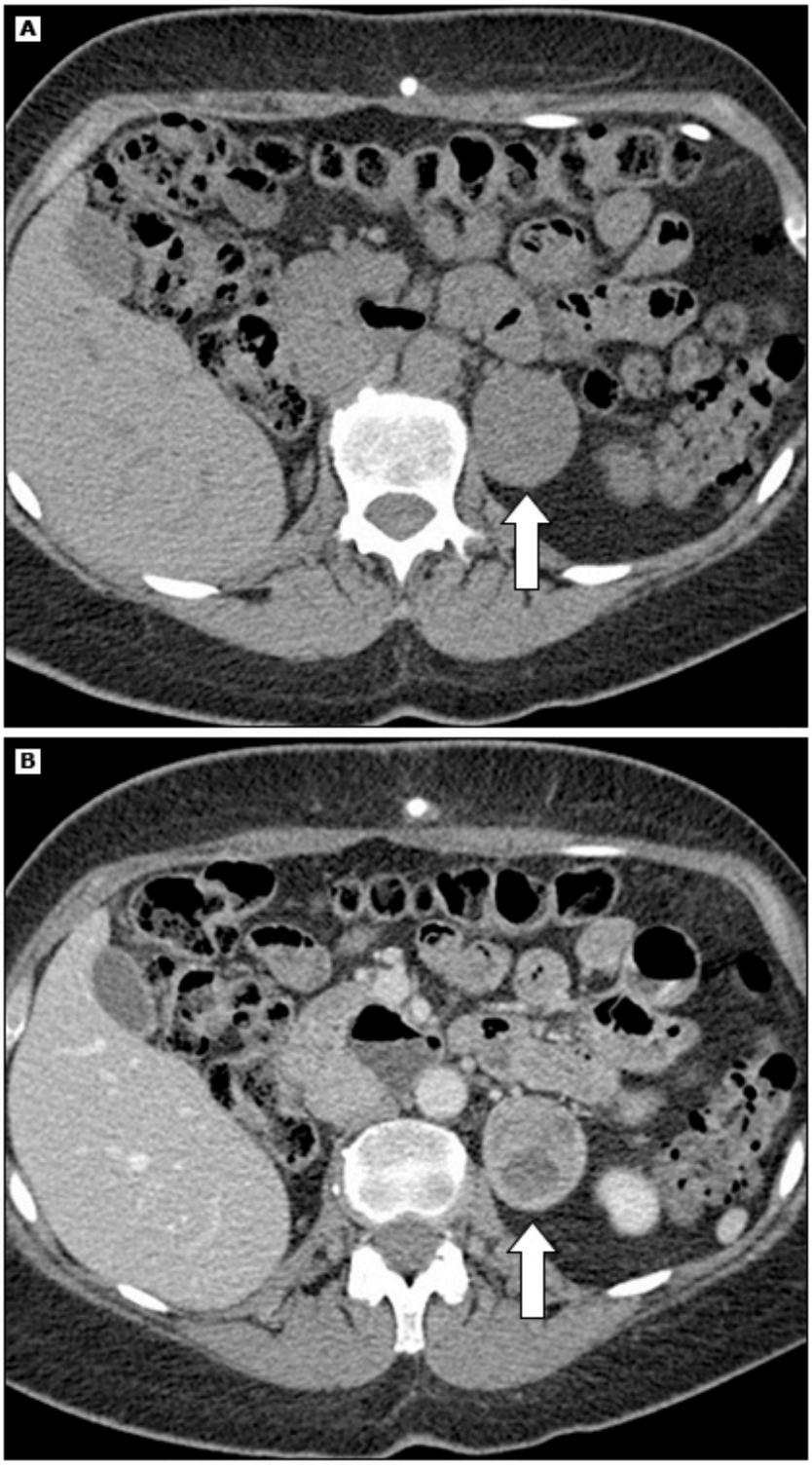

Unenhanced (A) and enhanced (B) axial CT images of an incidentally discovered 4.5 × 3.8 × 3.5 cm left adrenal mass (arrows). On the unenhanced image, the CT attenuation was 25 HU and diagnostic of a lipid-poor adrenal mass. With contrast administration, the adrenal mass was shown to be vascular and partially cystic (B), enhanced inhomogenously, and had slow contrast washout (<50% at 10 minutes). Biochemical evaluation was diagnostic of a noradrenergic pheochromocytoma with 24-hour urine normetanephrine of 4319 mcg (normal <900 mcg) and metanephrine of 250 mcg (normal <400 mcg).

CT: computed tomography; HU: Houndsfield units.

Courtesy of William F Young, Jr, MD.

Graphic 52609 Version 4.0

Image 3: **MRI of pheochromocytoma**

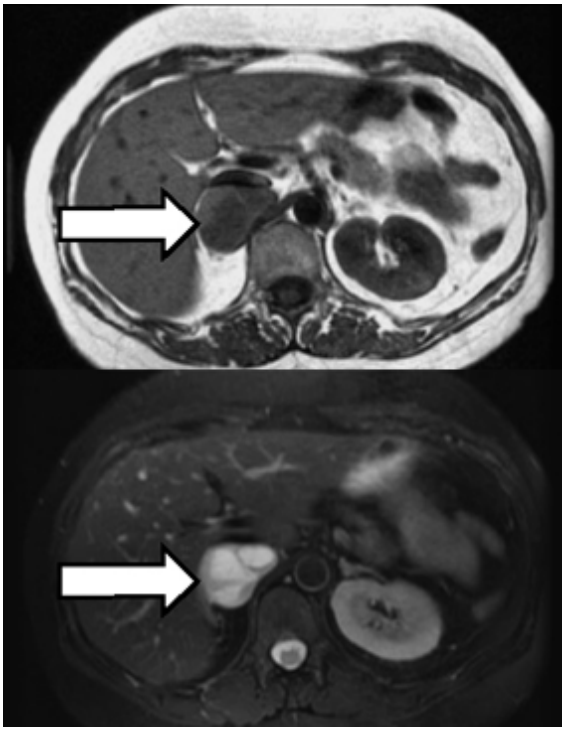

MRI of the abdomen shows a 4.5 cm right adrenal pheochromocytoma (arrows).
Upper panel: T1-weighted image.
Lower panel: T2-weighted image shows increased signal intensity typical of a pheochromocytoma.

MRI: magnetic resonance imaging.

Courtesy of William F Young, Jr, MD.

Graphic 75766 Version 4.0

Image 4: **Nonfunctioning adrenocortical carcinoma**

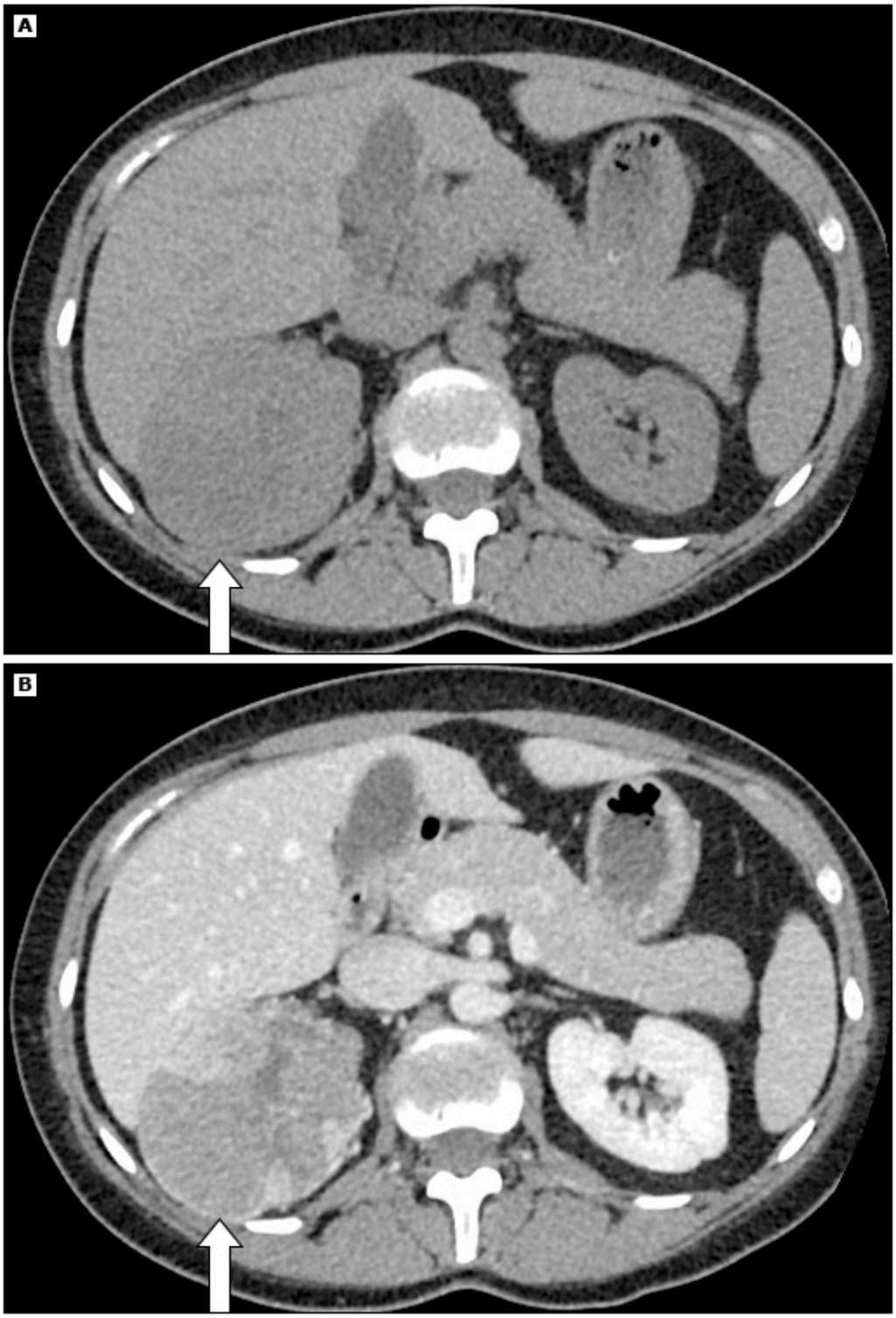

Unenhanced (A) and enhanced (B) axial CT images from a 22-year-old female who presented with left lower quadrant abdominal pain. An 8 cm right adrenal mass was discovered (arrows). On the unenhanced image, the CT attenuation was 34 HU and diagnostic of a lipid-poor adrenal mass. With contrast administration, the adrenal mass was shown to be vascular (B), enhanced inhomogenously, and had slow contrast washout (<50% at 10 minutes). All adrenal function tests were normal. At surgery, this tumor proved to be a 269 gram adrenal cortical carcinoma measuring 12 × 8 × 5.5 cm.

CT: computed tomography; HU: Houndsfield units.

Courtesy of William F Young, Jr, MD.

Graphic 53633 Version 6.0

Image 5: **Bilateral adrenal masses due to metastatic renal cell carcinoma**

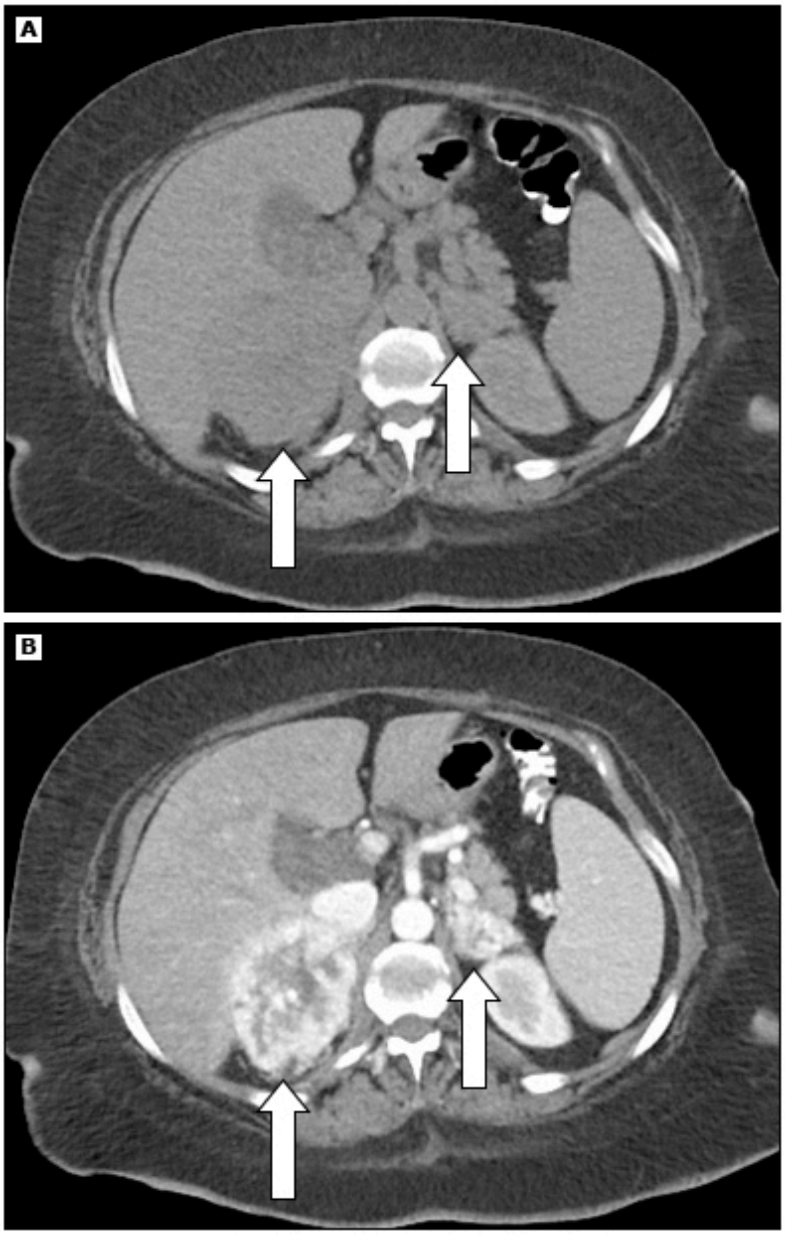

Unenhanced (A) and enhanced (B) axial CT images from a 54-year-old female who presented with shortness of breath. A chest CT scan had been performed to screen for pulmonary embolus and incidentally detected bilateral adrenal masses (arrows). In a subsequent abdominal CT scan, the right adrenal mass measured 11.7 × 8.6 × 9.1 cm with an unenhanced CT attenuation of 35 HU. The left adrenal mass measured 5.4 cm in maximum diameter and had an unenhanced CT attenuation of 39 HU. With contrast administration, both adrenal masses enhanced markedly and inhomogenously (B), and both had slow contrast washout (<50% at 10 minutes). The abdominal CT scan also detected a large right renal mass, which proved to be renal cell carcinoma. After excluding pheochromocytoma, biopsy of the right adrenal mass documented metastatic renal cell carcinoma.

CT: computed tomography; HU: Houndsfield units.

Courtesy of William F Young, Jr, MD.

Graphic 126149 Version 2.0

Image 6: **Adrenal myelolipoma**

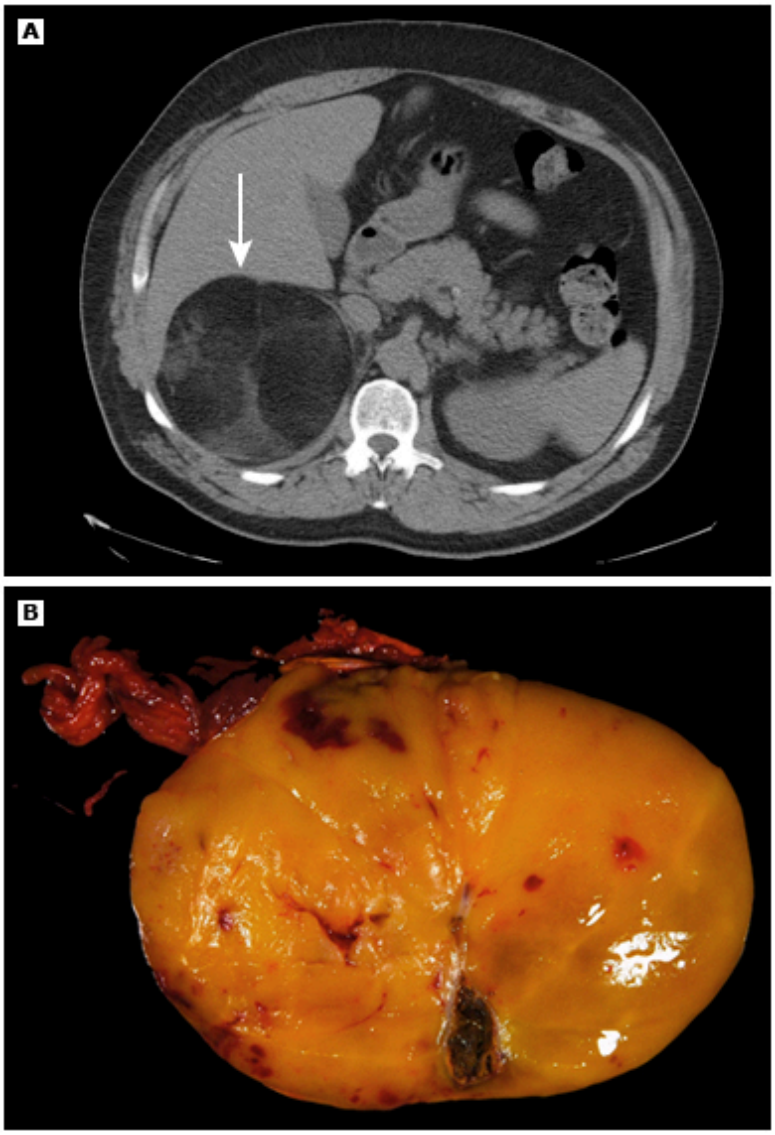

(A) Axial image from abdominal CT scan shows an 11 x 15 cm mixed signal intensity right adrenal mass (arrow) with large amounts of macroscopic fat consistent with adrenal myelolipoma.
(B) Gross pathology cut section showing a 19 x 12 x 9.5 1030 gm adrenal myelolipoma.

CT: computed tomography.

Graphic 72437 Version 3.0

Algorithm 1: **Approach to the patient with an adrenal incidentaloma**

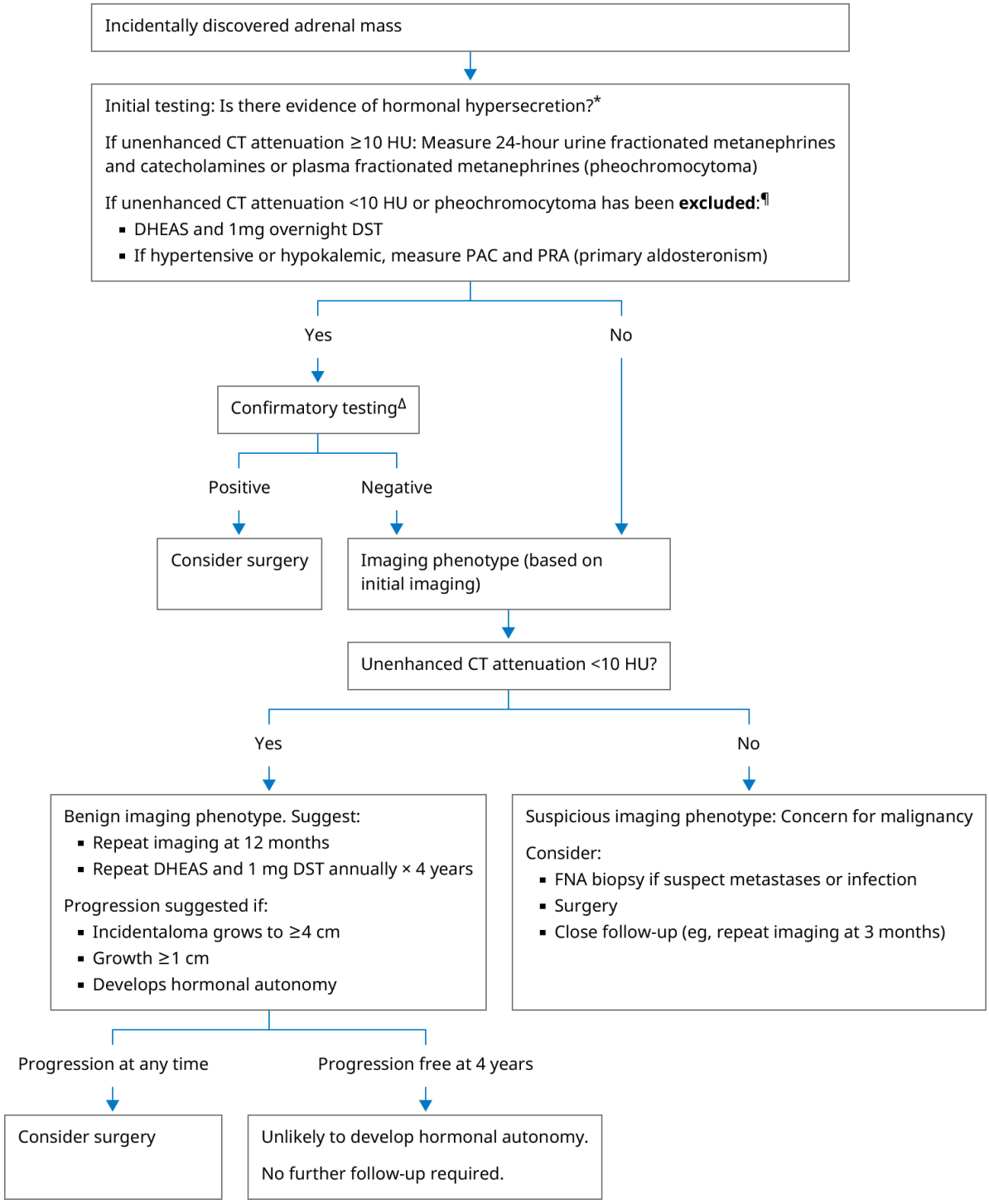

This algorithm must be used in conjunction with the UpToDate topic on the evaluation and management of the adrenal incidentaloma that describes biochemical evaluation followed by confirmatory testing if needed, as well as imaging features.

CT: computed tomography; DHEAS: dehydroepiandrosterone sulfate; DST: dexamethasone suppression test; FNA: fine-needle aspiration; HU: Houndsfield units; PAC: plasma aldosterone concentration; PRA: plasma renin activity.

* The initial biochemical testing is to determine if the incidentaloma is hormonally active. Testing is performed for subclinical hypercortisolism, pheochromocytoma, and primary aldosteronism.

¶ The overnight DST should not be performed if the unenhanced CT attenuation is ≥10 HU and pheochromocytoma has not been excluded through biochemical testing. In patients with pheochromocytoma, DST can precipitate catecholaminergic crisis.

Δ If there is evidence of hormonal hypersecretion, additional confirmatory testing is performed (refer to related UpToDate content on the evaluation and management of the adrenal incidentaloma).

Graphic 126129 Version 4.0

Image 7: **Bilateral macronodular adrenocortical hyperplasia**

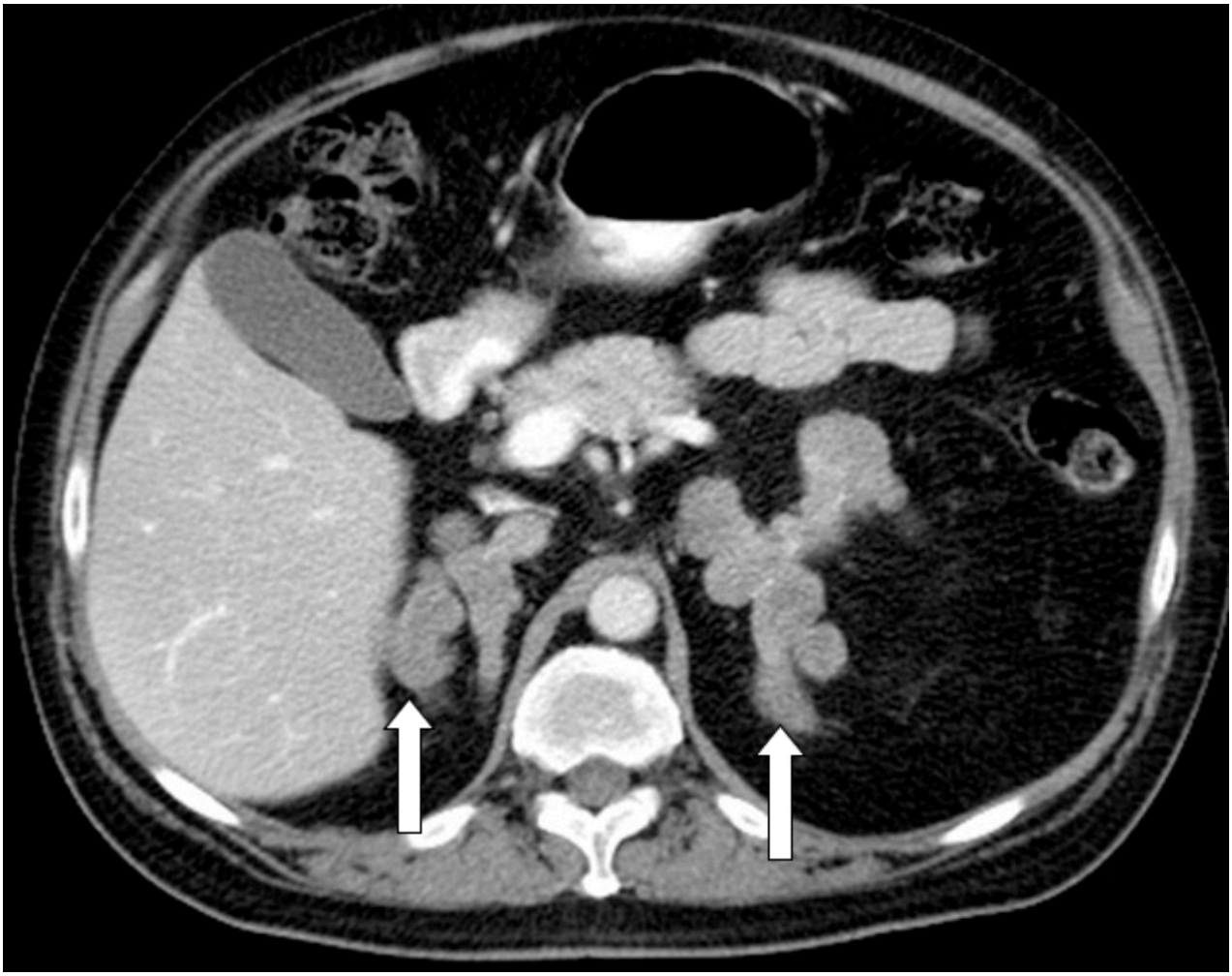

Contrast-enhanced axial CT image demonstrating massively enlarged adrenal glands (arrows) that are multinodular and adreniform in shape. This image is diagnostic of BMAH.

CT: computed tomography; BMAH: bilateral macronodular adrenocortical hyperplasia.

Courtesy of William F Young, Jr, MD.

Graphic 126150 Version 1.0

Image 8: **Small prebiochemical pheochromocytoma**

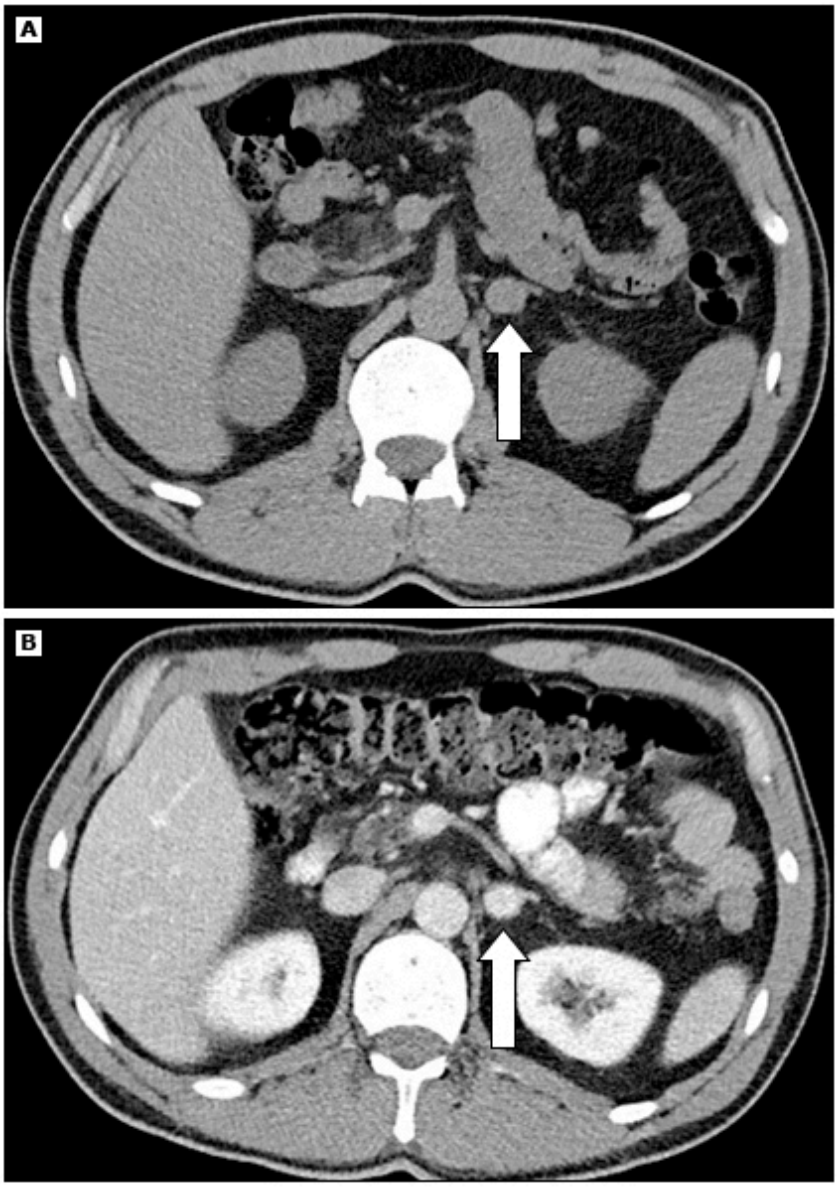

Unenhanced (A) and enhanced (B) axial CT images from a 49-year-old male who presented with right-sided abdominal discomfort. A 1.6 cm left adrenal mass was incidentally discovered (arrows). On the unenhanced image, the CT attenuation was 40 HU and diagnostic of a lipid-poor mass. With contrast administration, the adrenal nodule was very vascular (B) and had slow contrast washout (<50% at 10 minutes). The patient was normotensive and had no signs or symptoms of adrenal-related disease. The plasma fractionated metanephrines and 24-hour urine fractionated metanephrines and catecholamines were normal. However, in view of the suspicious imaging phenotype and the patient's young age, surgical resection after alpha-adrenergic blockade was advised. On pathology, it proved to be a 2.1 × 1.7 × 1.3 cm pheochromocytoma.

CT: computed tomography; HU: Houndsfield units.

Courtesy of William F Young, Jr, MD.

Graphic 126151 Version 2.0

Contributor Disclosures

William F Young, Jr, MD, MSc Consultant/Advisory Boards: AstraZeneca Pharmaceuticals [Biologic effects of aldosterone synthase inhibitors]; Crinetics Pharmaceuticals - Scientific advisory board [Discovery drugs for rare endocrine diseases]; Roche Diagnostics Corporation [Laboratory assays for detection of catecholamine-secreting tumors and primary aldosteronism]. All of the relevant financial relationships listed have been mitigated. **Electron Kebebew, MD, FACS** No relevant financial relationship(s) with ineligible companies to disclose. **Lynnette K Nieman, MD** Grant/Research/Clinical Trial Support: Crinetics Pharmaceuticals, Inc [Cushing's syndrome]. All of the relevant financial relationships listed have been mitigated. **Sally E Carty, MD, FACS** Other Financial Interest: Jaypee Brothers [Endocrine surgery]. All of the relevant financial relationships listed have been mitigated. **Katya Rubinow, MD** No relevant financial relationship(s) with ineligible companies to disclose. **Wenliang Chen, MD, PhD** No relevant financial relationship(s) with ineligible companies to disclose.

Contributor disclosures are reviewed for conflicts of interest by the editorial group. When found, these are addressed by vetting through a multi-level review process, and through requirements for references to be provided to support the content. Appropriately referenced content is required of all authors and must conform to UpToDate standards of evidence.

Conflict of interest policy

→